

# SYNCHRONIZED RF & HIFEM: HISTOLOGICAL EVALUATION OF THE EFFECT ON FAT IN HUMANS

## HISTOLOGICAL EVALUATION OF THE SIMULTANEOUS RF AND HIFEM TREATMENTS ON HUMAN FAT TISSUE

Radina Denkova MD.

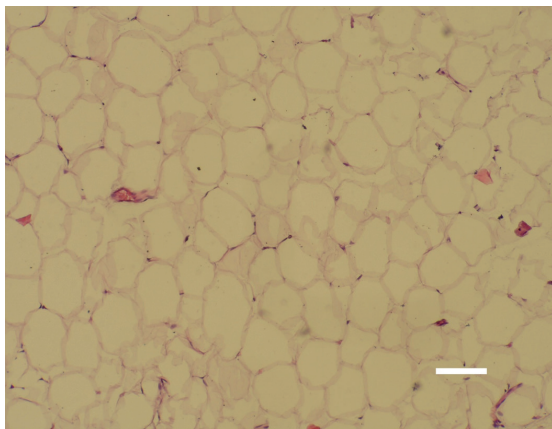
1. Aesthetic Clinic Beauty, Sofia, BG

Source: U.S. Food and Drug Administration. 510(k) Premarket Notification: K192224. Published online December 5, 2019.

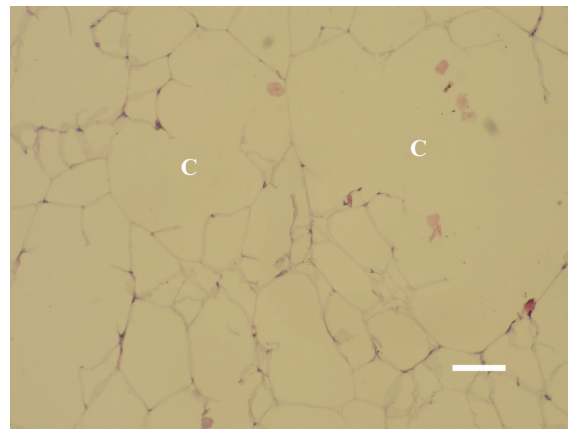
### HIGHLIGHTS

- **Intensive fat cell disruption peaking at 20 days post-treatment.**
- **Non-invasive lipolysis** seen in the **first 10 days** post-treatment.
- Investigated device was found to be effective for **elimination of fat cells.**
- **No damage** to skin, sweat glands and sebaceous glands was observed, ensuring procedural safety.
- **Deformed nucleus** and **pyknotic nucleus** indicating **cell death.**

BASELINE



20 DAYS AFTER



Normal subcutaneous tissue morphology with typical uniform size of adipocytes at the left; bar = 40 micrometers. Intensive fat cell disruption (C) and alternation of adipocytes shape 20 days post-treatment at the right; bar = 30 micrometers.